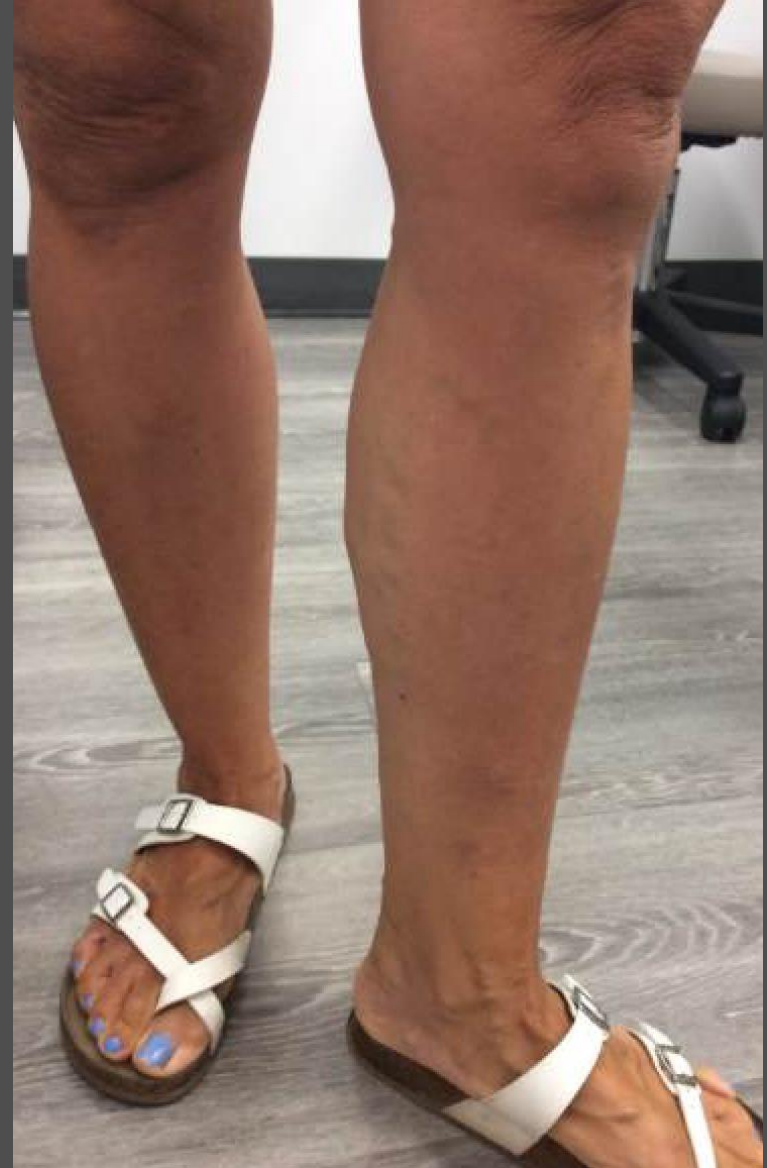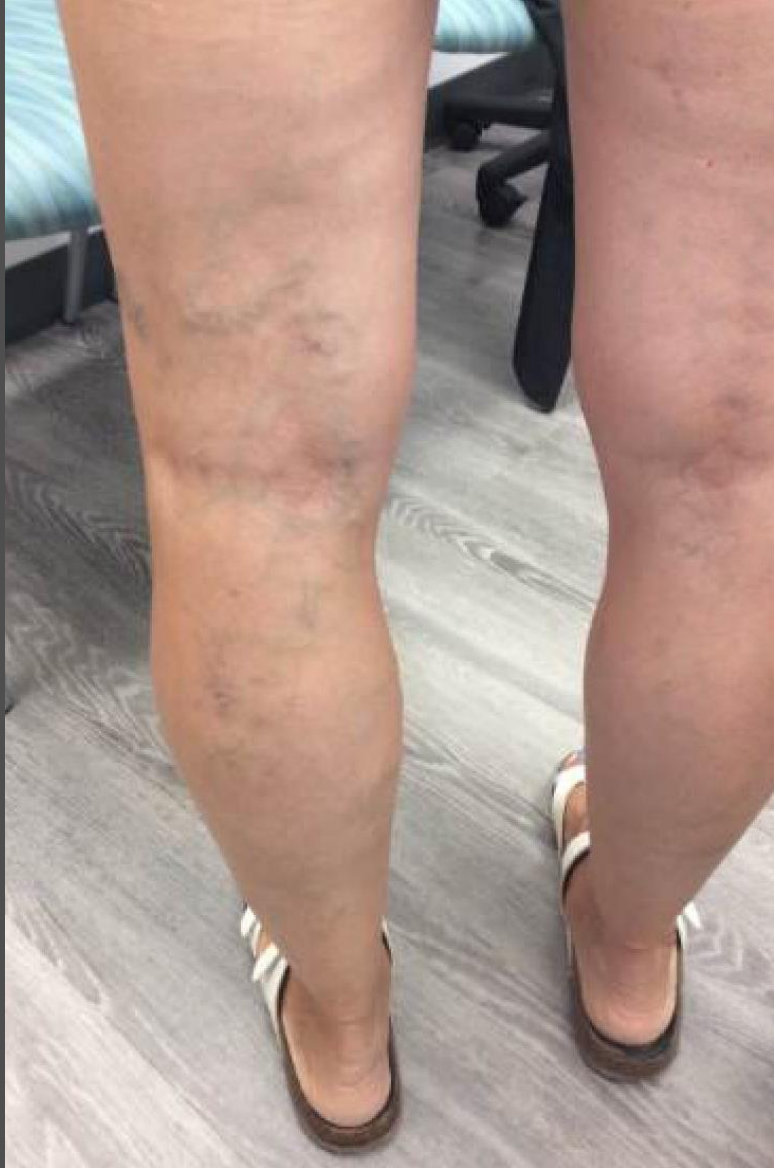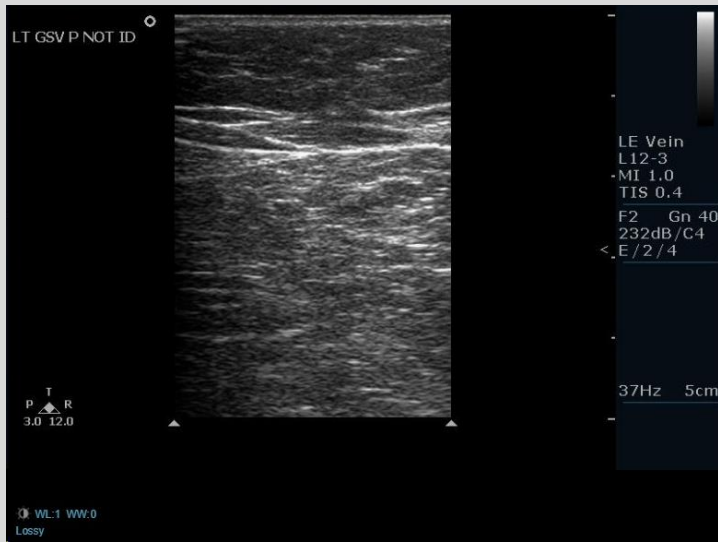


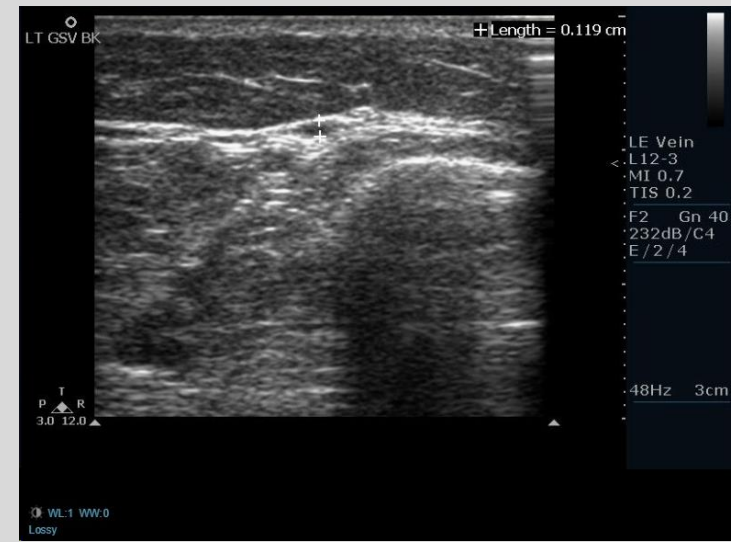
Persistent varicose veins after GSV ablation

- 56-year-old female with symptomatic left lower limb varicose veins
- Symptoms: She feels heaviness, achiness with standing. She used compression stockings with improvement, but they are not so comfortable to wear
- PMH – Left GSV laser ablation in 2016
 - After her procedure she was not happy as her varicose veins decreased slightly in size, but her symptoms did not completely resolve
 - She did not follow up and comes now with worsening symptoms
 - Denies pelvic symptoms

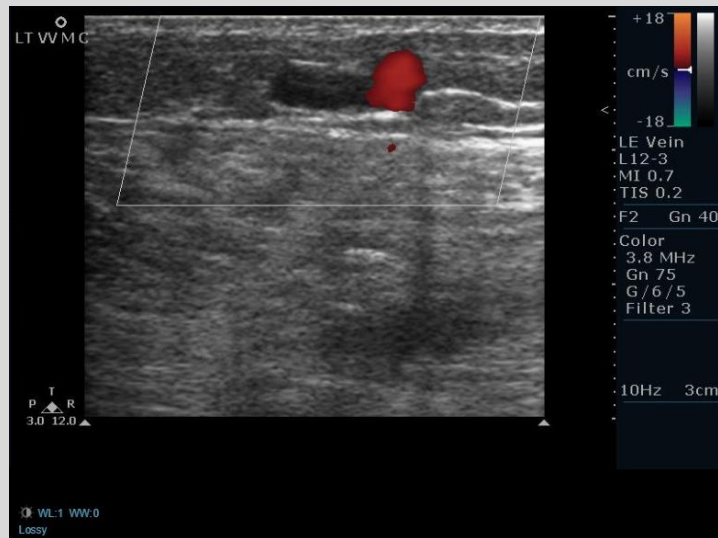




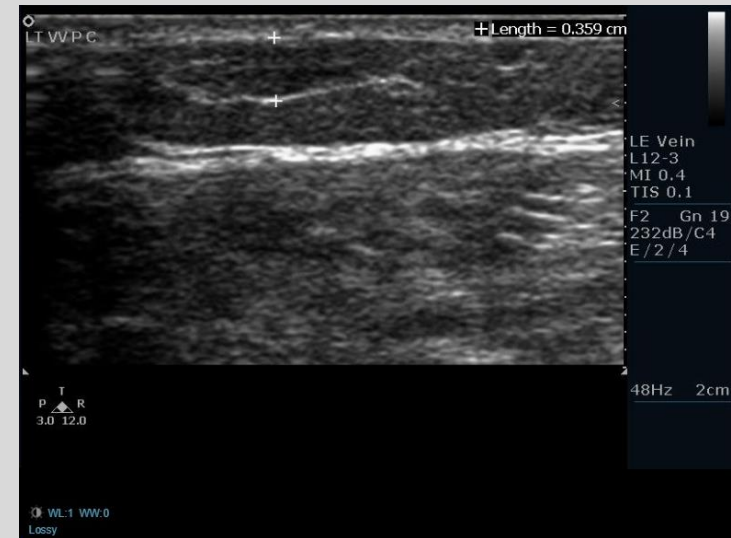GSV in thigh not visualized



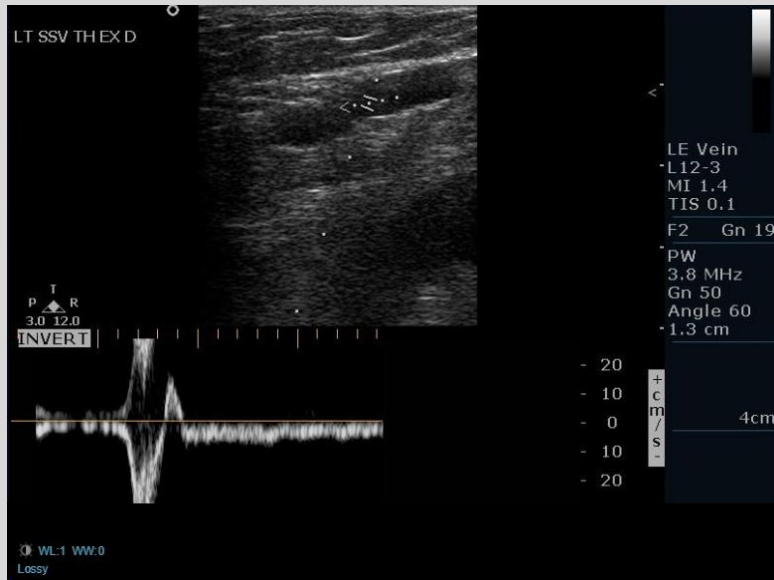
GSV in calf not visualized



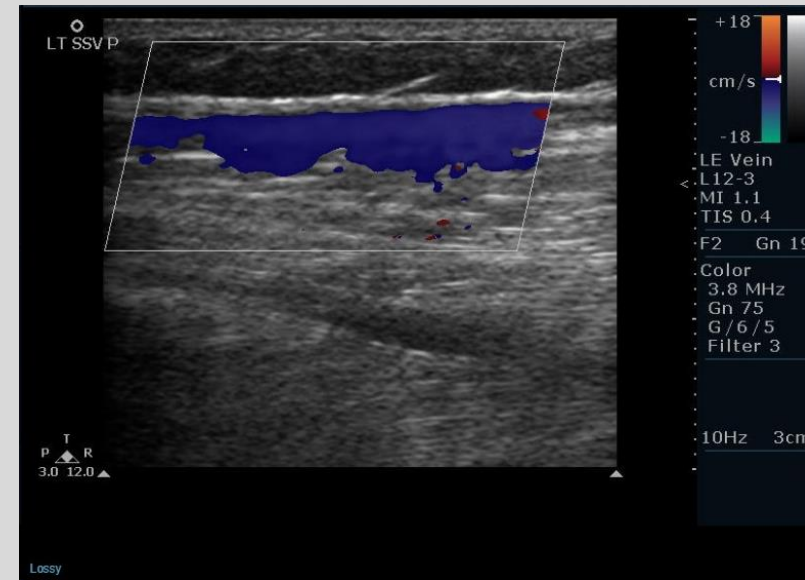
Medial thigh varicose veins with reflux



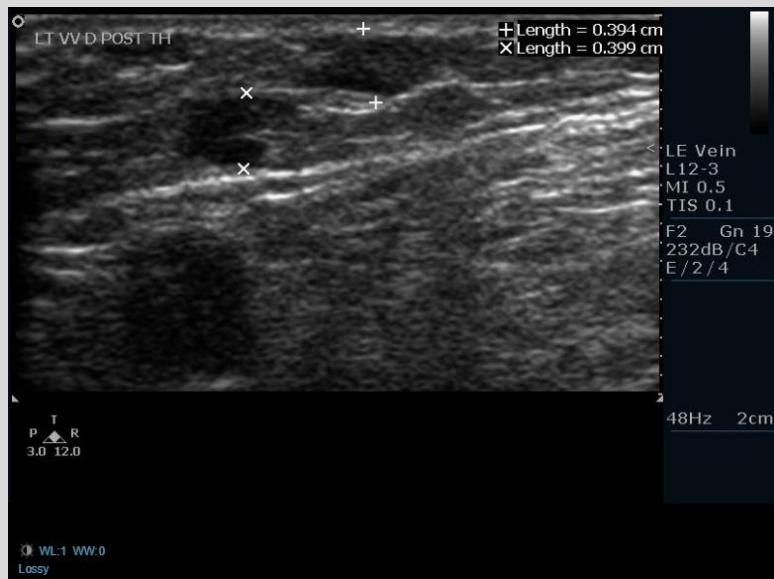
Medial thigh varicose veins 4mm



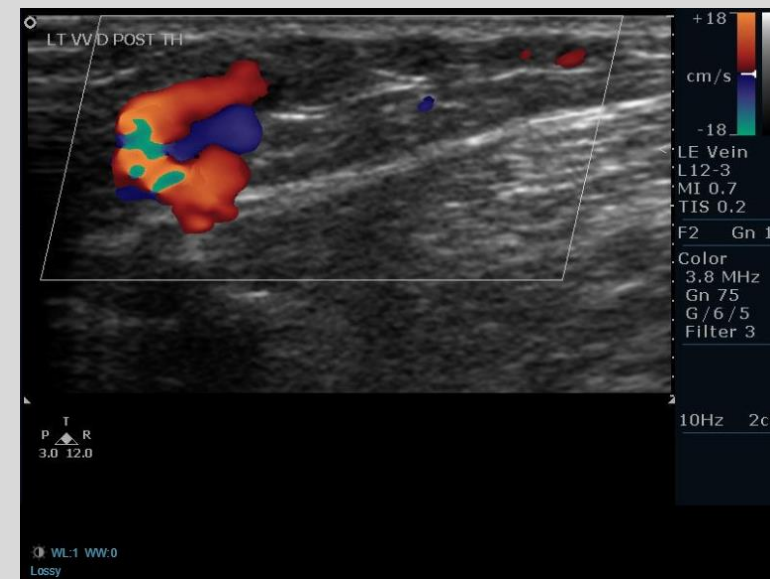
SSV thigh-extension with no reflux



SSV with no reflux



4mm varicose veins in posterior thigh



Varicose veins with reflux

Key clinical questions:

- When treating GSV reflux should varicose veins be addressed at same time or staged?
- With distribution of varicose veins in posterior thigh, is pelvic evaluation necessary in this patient?
- How to best treat posterior thigh varicosities?

Talks to
address
these clinical
questions at
VS2020

VS Debate Treatment of vein tributaries is paramount Treatment of vein tributaries is secondary	Kathy Gibson Steve Elias
Practical Approach in the management of varicosities	Peter Pappas
Management of patient with...Thigh Extension Of The Small Saphenous Vein	Harold Welch
Varicose Veins Associated With ... Previous Saphenous Ablation	Kathleen Gibson
Pelvic vein disease	Melvin Rosenblatt
Where to look with non-saphenous veins	Tony Gasparis
