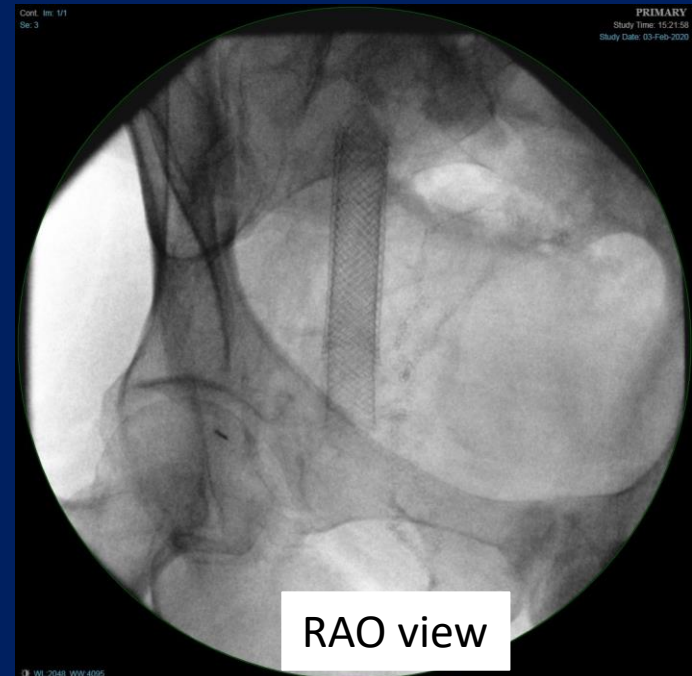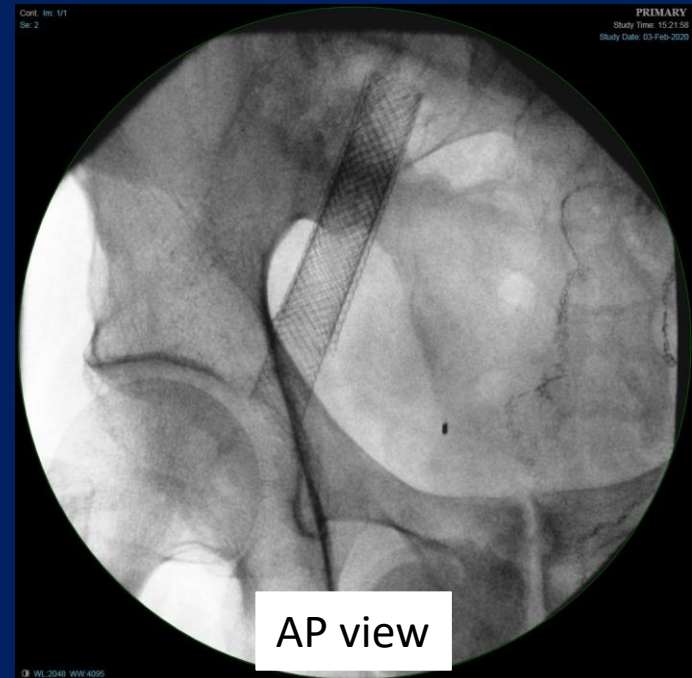


- 53-year-old male underwent right leg thrombolysis and stent placement of EIV on 3/2018 for iliofemoral DVT
- Returned 6/2018 with leg swelling and in-stent stenosis; underwent PTA and re-stent (14mm Wallstent)
- 6/2019 underwent placement of third stent extending to inguinal ligament for symptomatic in-stent stenosis



Present now with >50% diameter stenosis proximal to the stent.

Denies any leg symptoms

At end Venous Symposium where there will be live imaging of this patient and discussion of treatment plan

