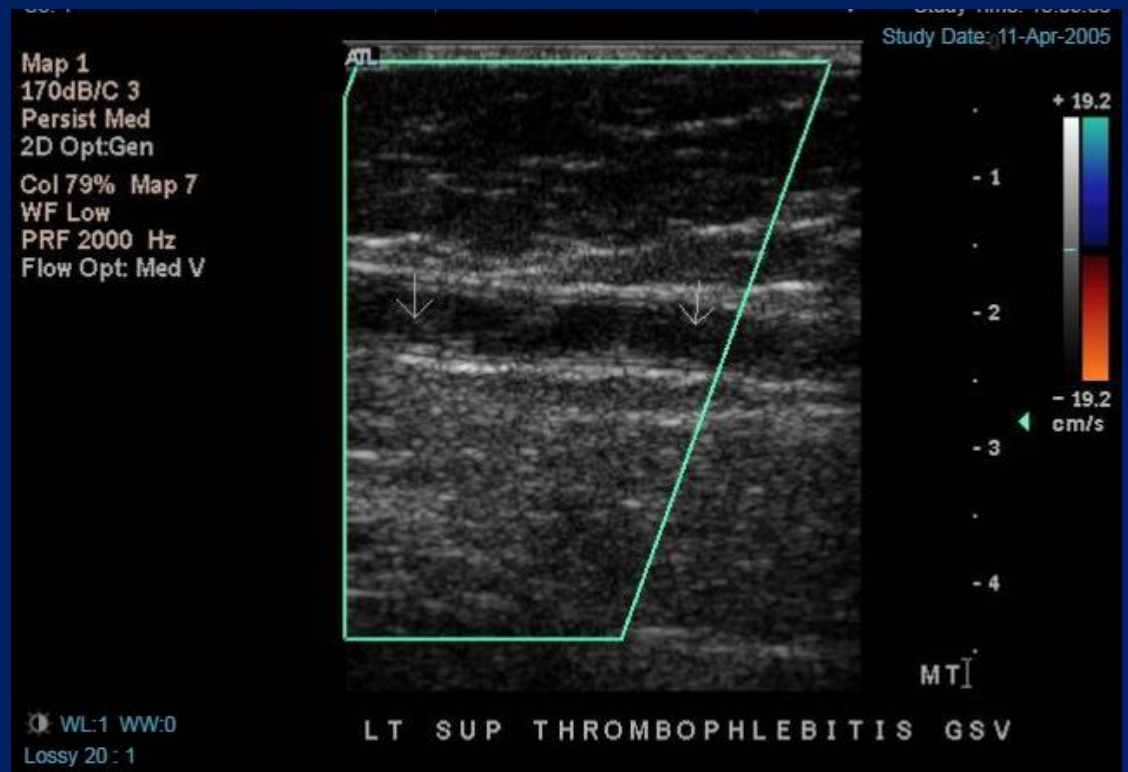


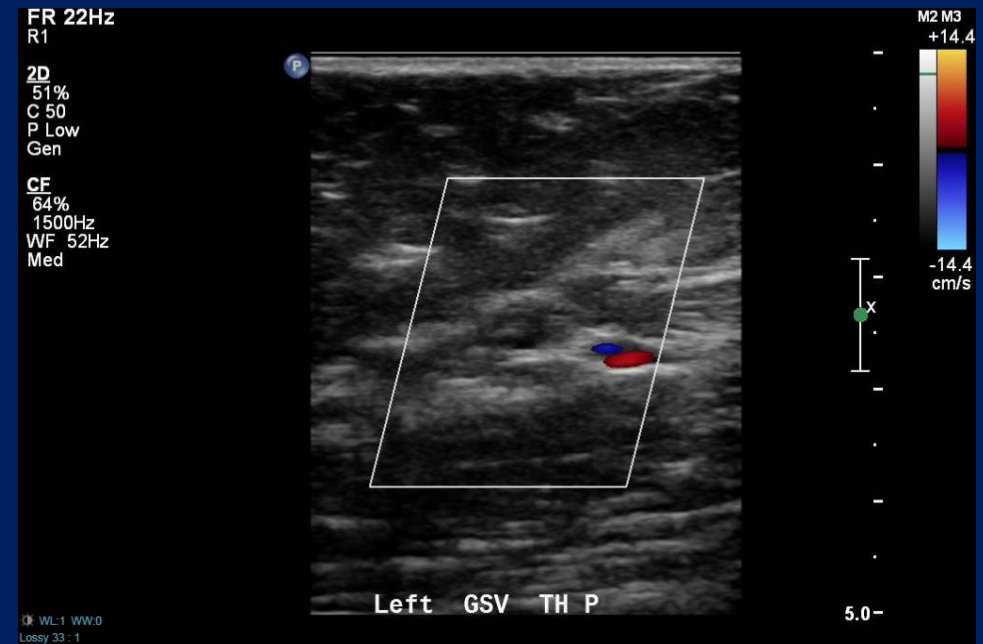
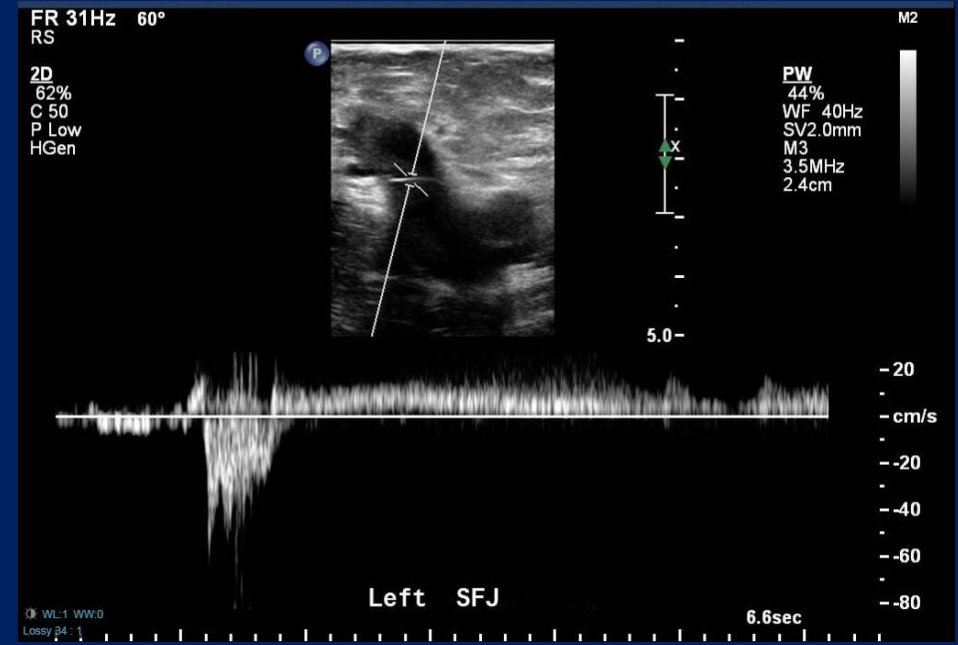- 54 yo who seen in 2005 and underwent ligation of GSV for a 5cm aneurysm
- Post procedure she developed GSV thrombophlebitis which resolved with conservative measures



- Presents now with bilateral varicose veins, symptomatic only in the left leg.

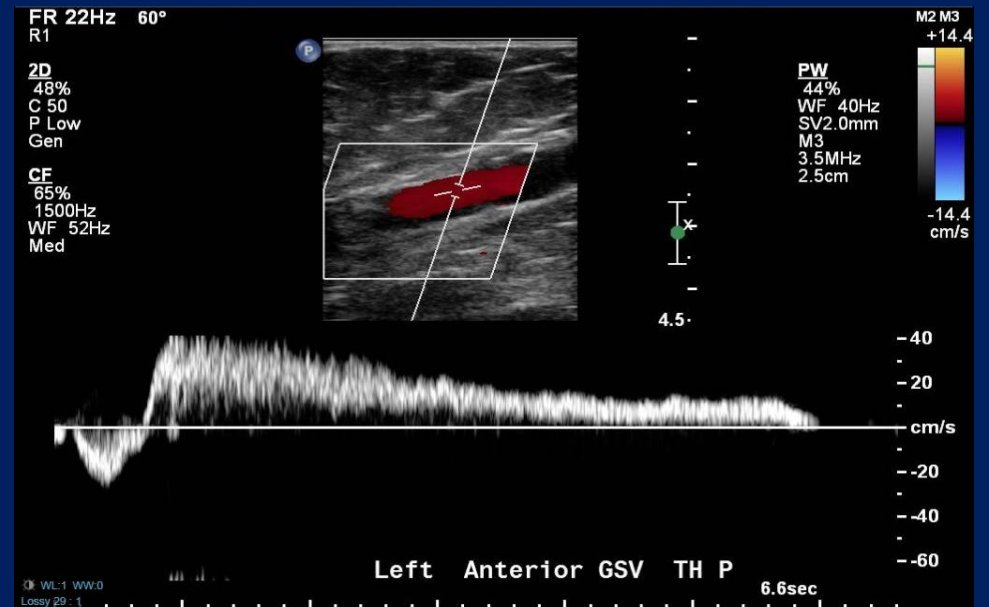
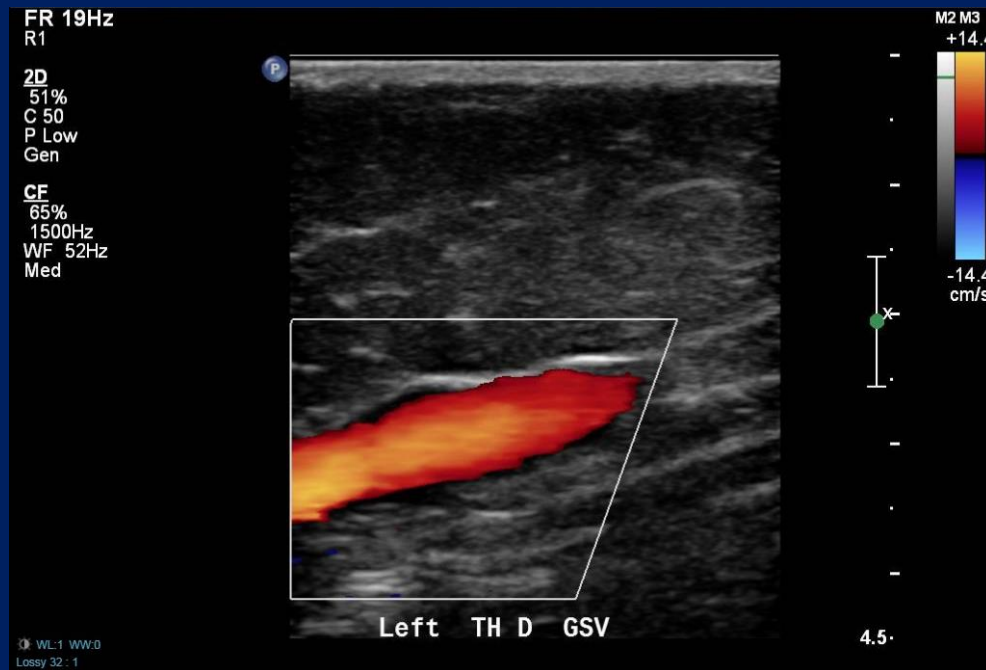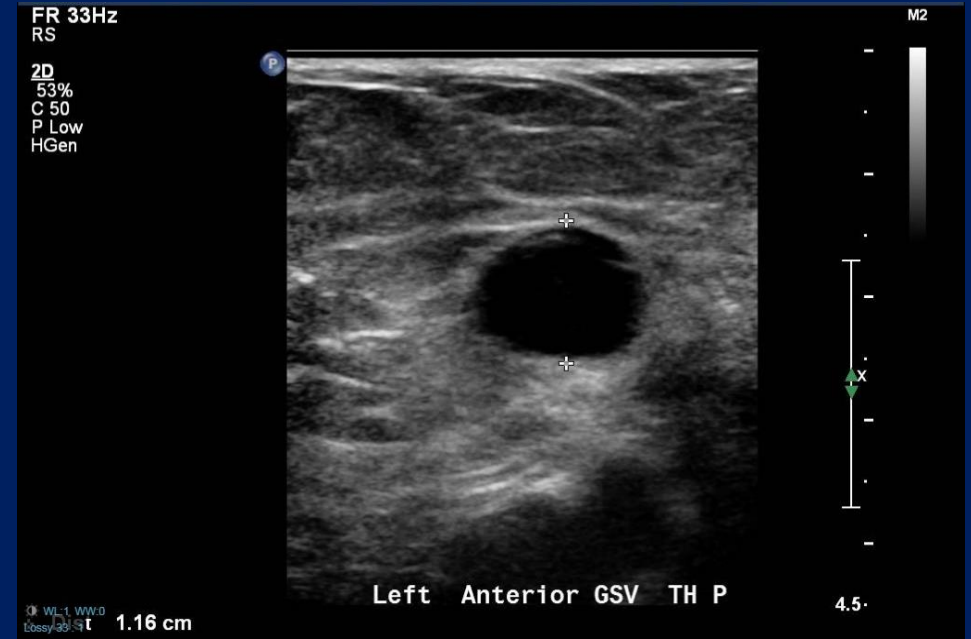
- **Duplex US**

- Reflux at SFJ
- Absent GSV in the proximal thigh



Duplex US

- 11.6mm AAGSV; reflux >5 sec
- Varicosities in the AAGSV connecting with distal GSV
- 8mm GSV in the distal-thigh with reflux



Findings

- Absent GSV from junction to distal thigh
- AAGSV with reflux
- Varicosities in the AAGSV connecting with distal GSV
- GSV reflux from distal thigh to calf

Attend Venous Symposium where there will be live imaging of this patient and discussion of treatment plan

